

Personal Practice of Female Pelvic Floor Medicine

Osamu Nishizawa, Osamu Ishizuka, Haruo Kato

Department of Urology, Shinshu University School of Medicine

Transvaginal Tape (TVT) operation

LUTS LOWER URINARY
TRACT SYMPTOMS



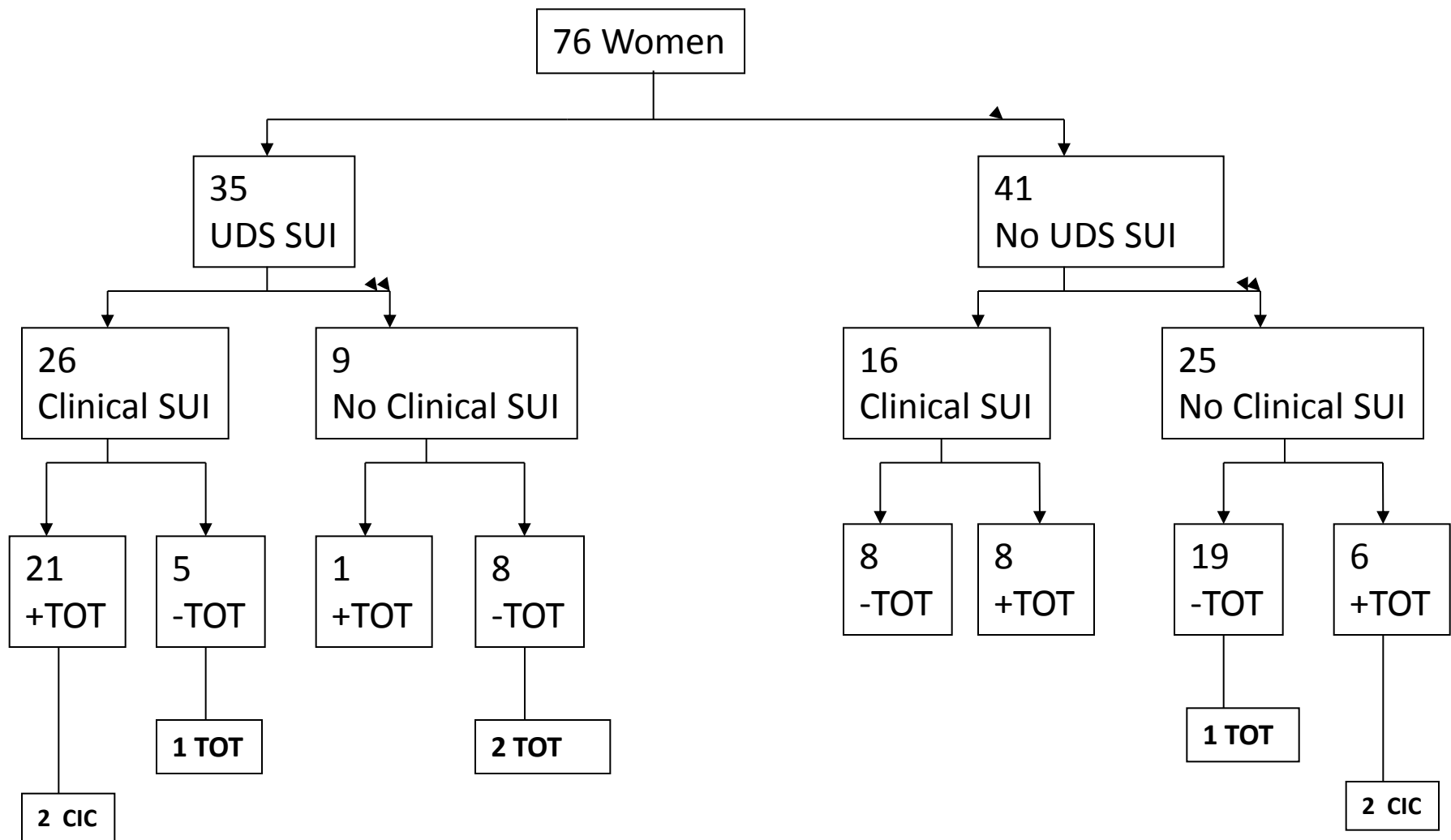
LUTS (2012) 4, 110–113

REVIEW ARTICLE

Videourodynamic Examination and Tension-free Vaginal Mesh/Transobturator Tape Surgery

Osamu NISHIZAWA,* Midori ICHINO, Masakuni ISHIKAWA, Tomoaki TANABE,
Hisanori SUZUKI, Tetsuichi SAITO, Tetsuya IMAMURA, and Osamu ISHIZUKA

Department of Urology, Shinshu University School of Medicine, Matsumoto, Japan



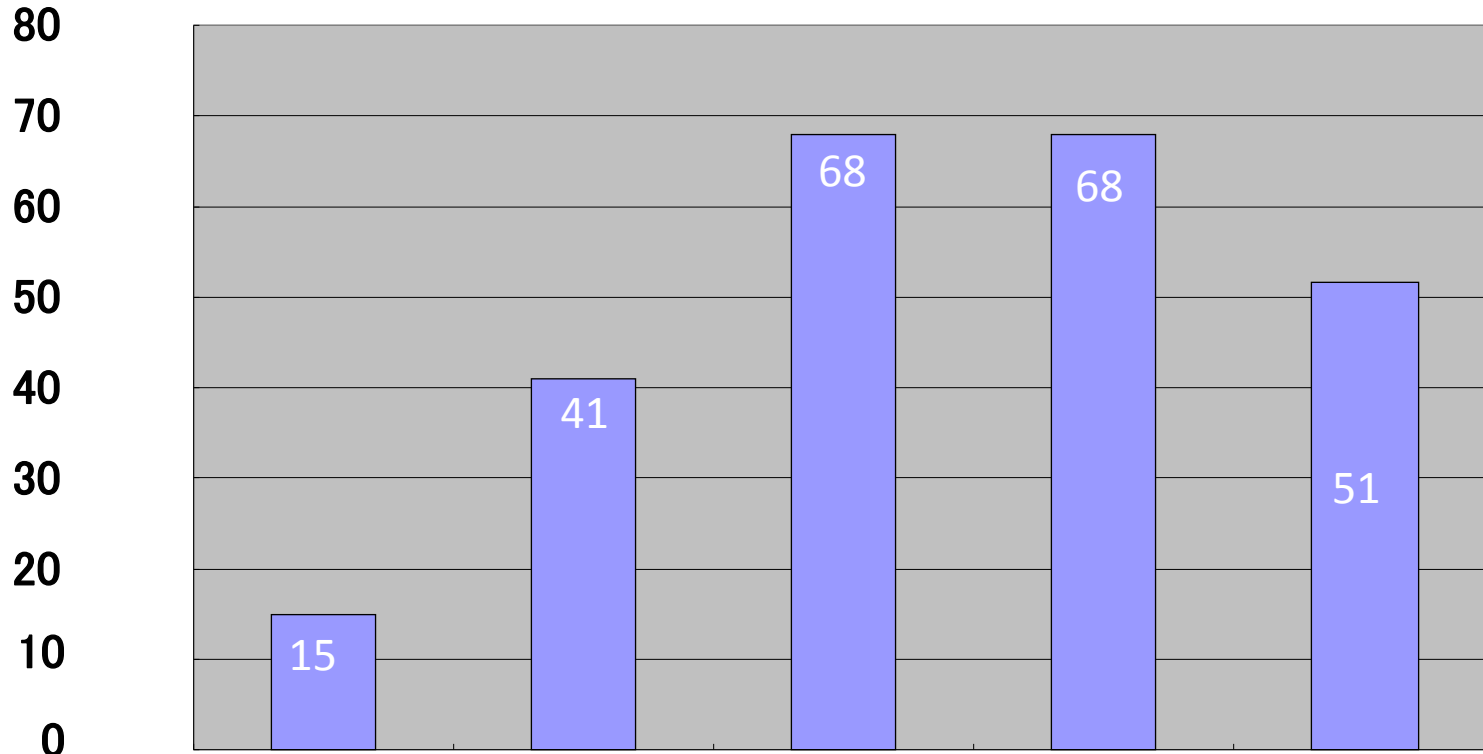
Between July 2008 and December 2010, among of 79 POP patients

Fig. 7 UDS SUI with or without clinical SUI and its surgical outcome in POP patients

Yearly number of TVM operation

2008/7 ~ 2013/6

243 operations



2008/7 ~
2009/6

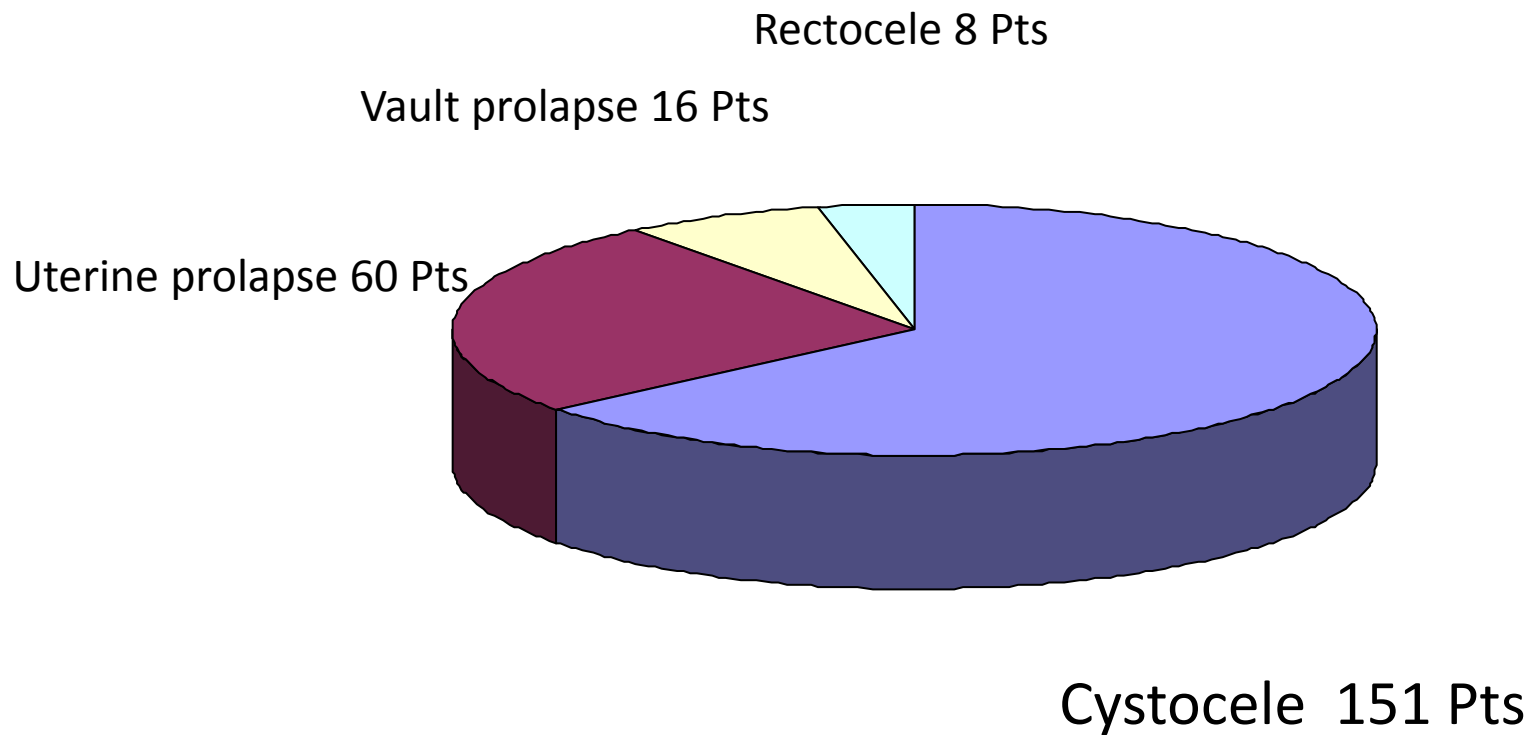
2009/7 ~
2010/6

2010/7 ~
2011/6

2011/7 ~
2012/6

2012/7 ~
2013/6

Classification of POP at first time operation



First time operation

Second time operation

Cystocele 151 Pts

A-TVM 151pts

P-TVM 9Pts

AP-TVM+hysterectomy 1Pt

**Uterine prolapse
60 Pts**

AP-TVM 54 Pts

AP-TVM+hysterectomy 4Pts

P-TVM 1 Pt

A-TVM 1Pt

A-TVM+hysterectomy 3 Pts

A-TVM 1Pt

**Vault prolapse
16 Pts**

C-TVM 16Pts

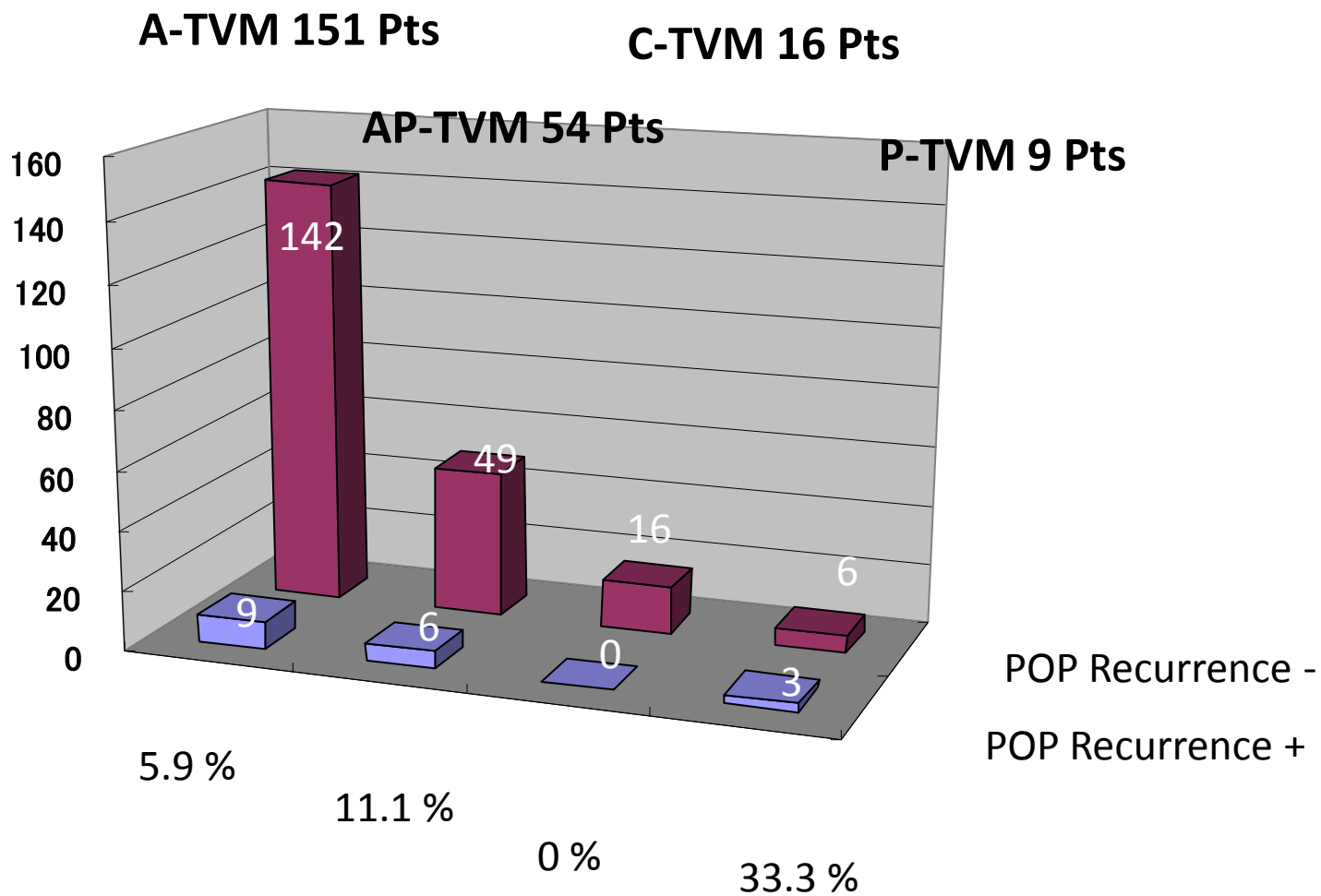
Rectocele 8 Pts

P-TVM 7Pts

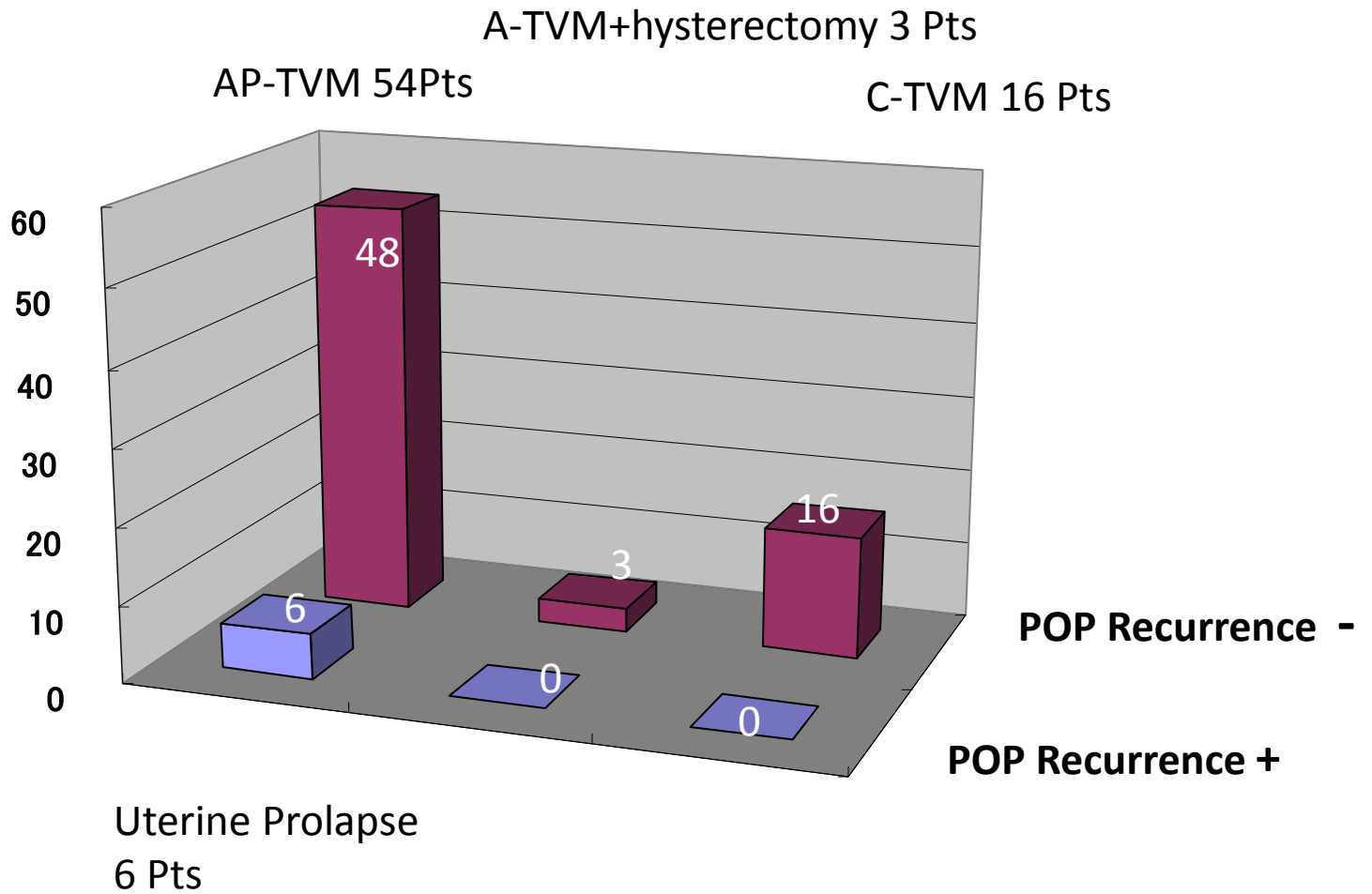
A-TVM 2 Pts

P-TVM+hysterectomy 1Pt





2008/7 ~ 2013/6

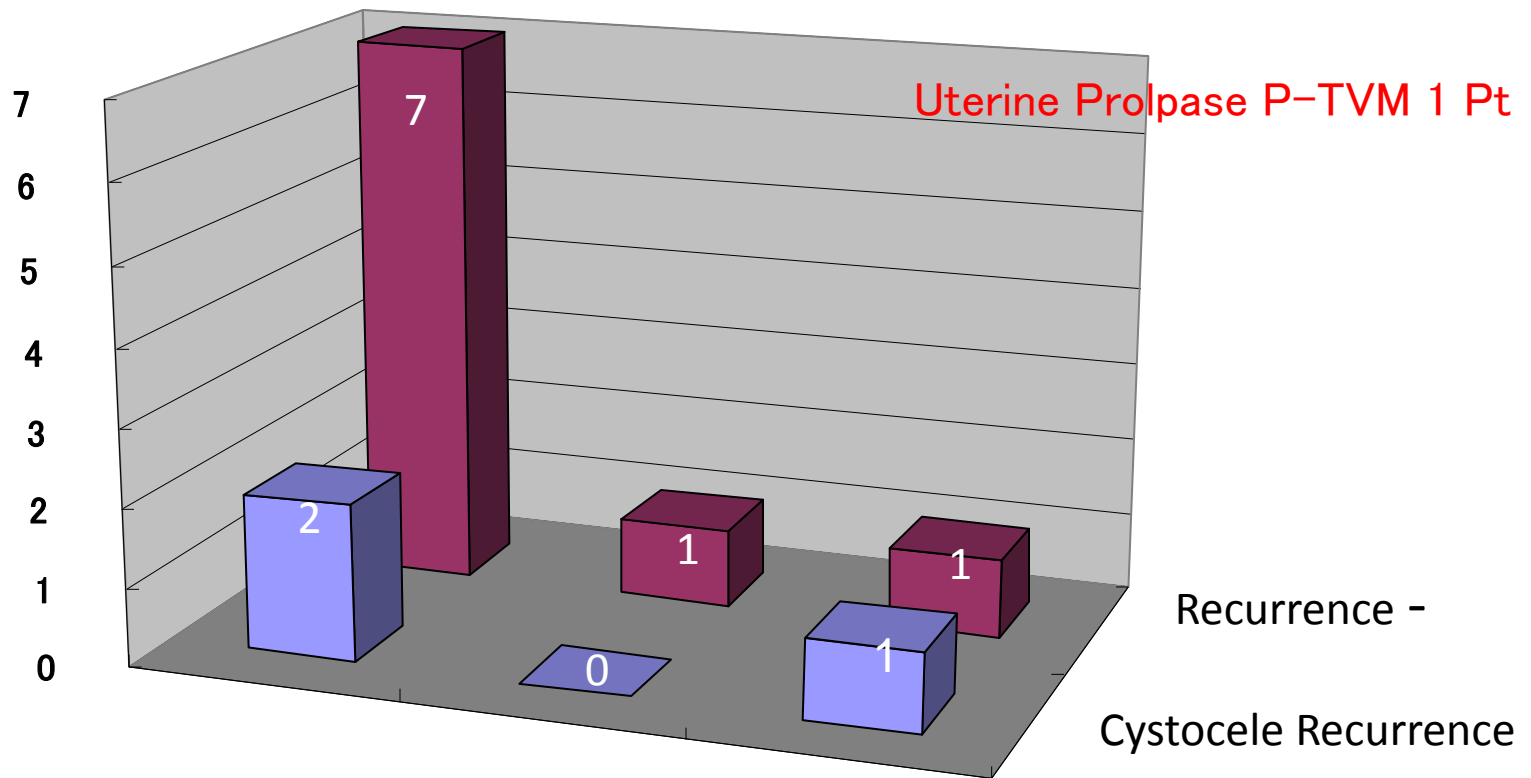


P-TVM 9 Pts

Rectocele P-TVM 7 Pts

Redctocele P-TVM +hysterectomy 1 Pt

Uterine Prolapse P-TVM 1 Pt

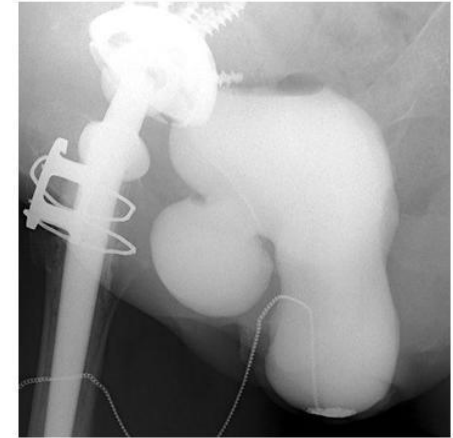
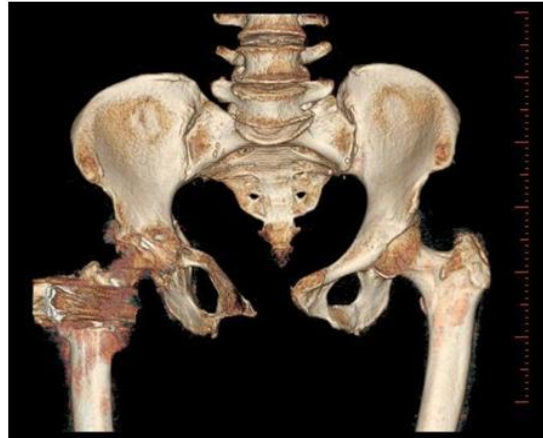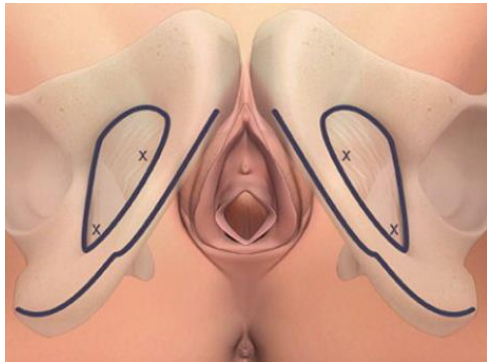


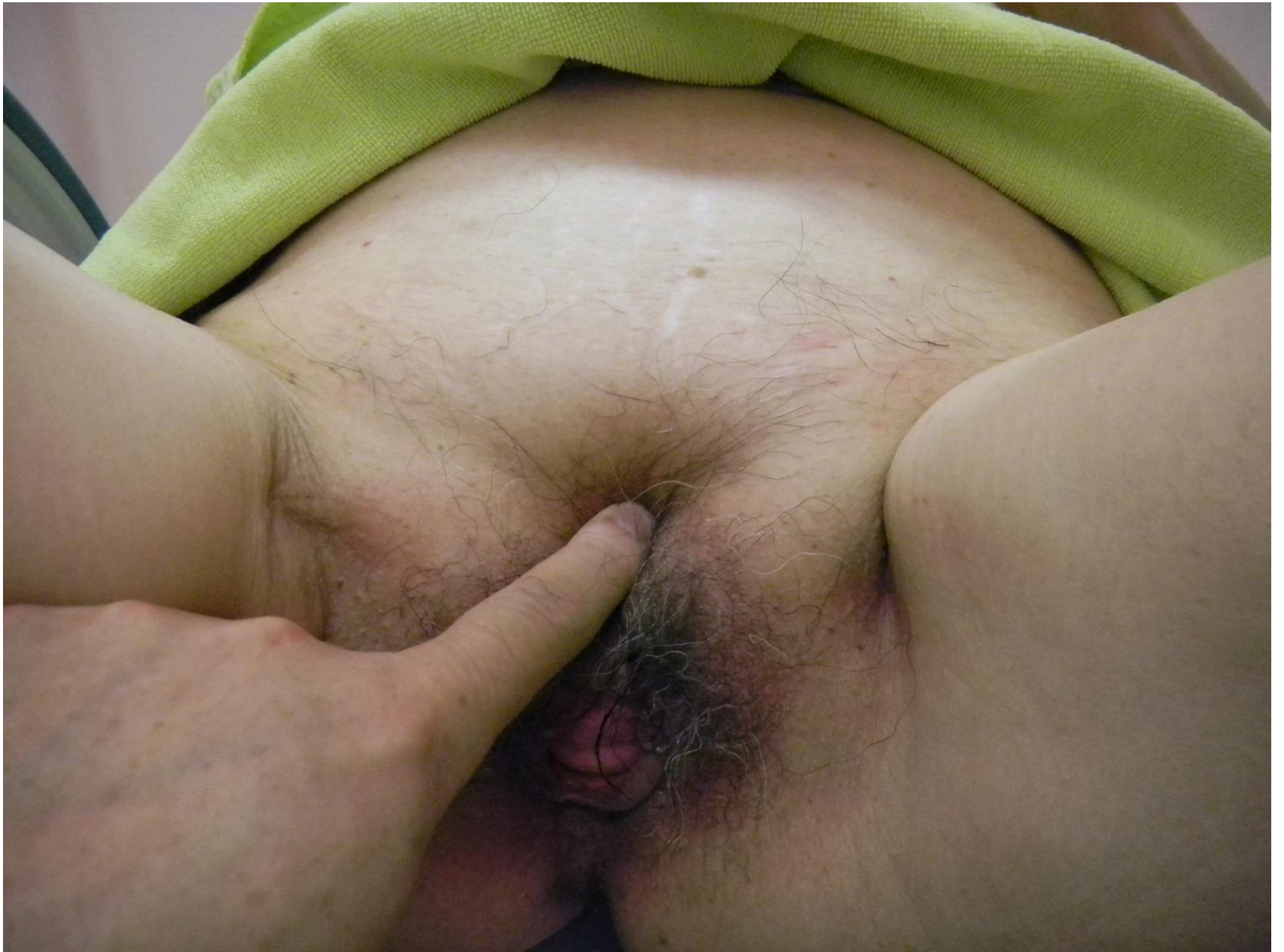Perspectives in Urology

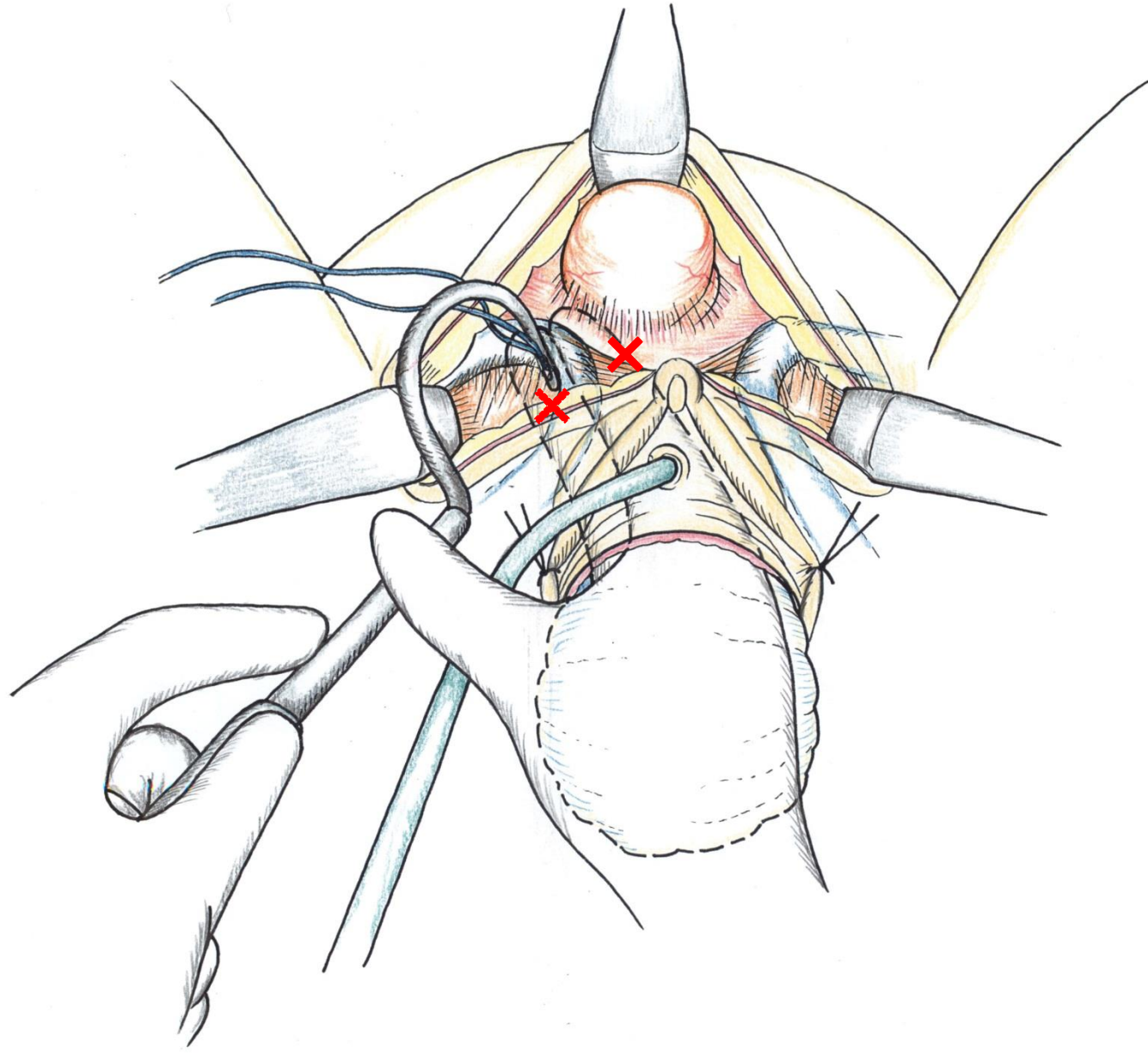
Advantages of self-tailored mesh for vaginal prolapse

Osamu Nishizawa, Haruaki Kato and Osamu Ishizuka

Department of Urology, Shinshu University School of Medicine, Matsumoto, Nagano, Japan







The self-tailored mesh provides wider indication for POP repair surgery. The indication for self-tailored mesh surgery includes vaginal prolapse where transobturator passage is unable to be used, and previous pelvic surgery by the abdominal approach and previous colporrhaphy by the vaginal approach.